

# Transient Non-Inflammatory Vascular Sheathing in Combined CRVO and Cilioretinal Artery

Imran Akram

*Pak J Ophthalmol 2018, Vol. 34, No. 2*

See end of article for authors affiliations

Correspondence to:  
Imran Akram  
Consultant Ophthalmic &  
Vitreoretinal Surgeon  
St Helens Hospital, UK  
Email:imranakram2020@gmail.com

To describe a case of evanescent sheathing of retinal vessels in a case of combined occlusion of the central retinal vein and Cilioretinal artery. The sheathing was non-inflammatory and resolved spontaneously after a few days. This was accompanied by significant visual improvement. No active treatment was offered to this patient. Even though transient vessel sheathing has been previously reported in retinal vein occlusion this is the first published report of transient vessel sheathing in association with combined central retinal vein and Cilioretinal artery occlusion.

**Key words:** Transient sheathing, Central retinal vein occlusion, Cilioretinal artery.

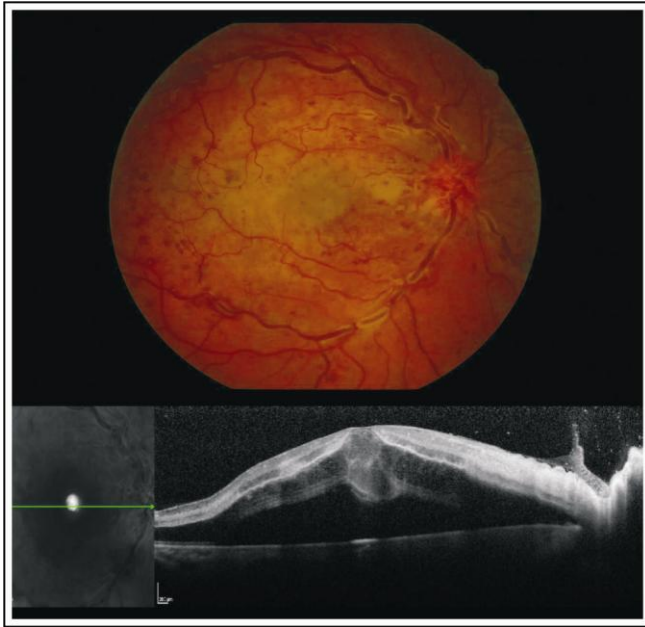
Central retinal vein occlusion associated with Cilioretinal artery occlusion is well documented<sup>1,2</sup>. It can occur even in the absence of reported systemic pathology<sup>3</sup> although most patients do have associated comorbidity<sup>4,5</sup>.

## CASE REPORT

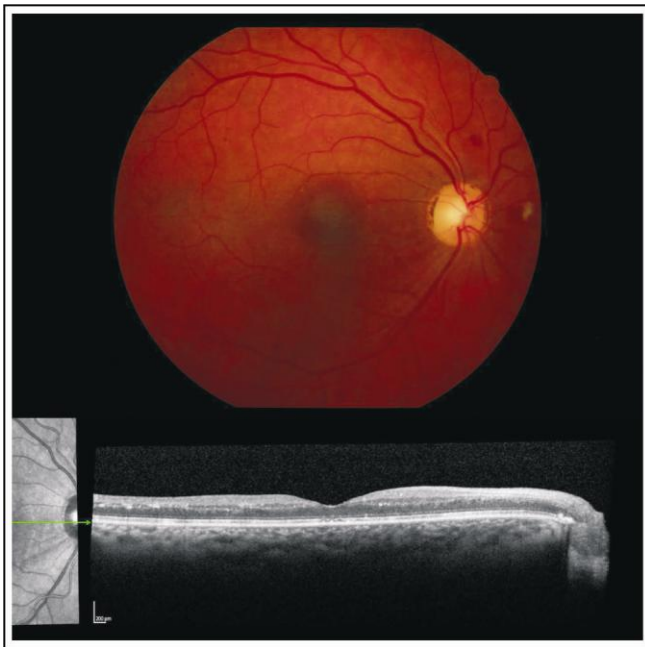
A 54-year-old Caucasian man presented to our unit with a 24-hour history of painless visual loss in his right eye. He was a non-smoker, had no medical history of note. Visual acuity was count fingers in the right eye, and 6/6 unaided left eye. Right eye showed a significant relative pupillary defect (RAPD++). Anterior segment was quiet. Fundus examination (Fig. 1) showed a hyperaemic swollen disc, dilated tortuous veins accompanied by blot haemorrhages in all quadrants. The veins in all quadrants demonstrated segmental sheathing. Some medium sized arterioles also demonstrated focal sheathing. There was no vitreous activity. There was a creamy pallor all over the posterior pole extending from temporal to the disc

and involving the macula. OCT scan (Fig. 1) showed macular SRF and hyper-reflectivity of the inner retina consistent with cloudy swelling. The left eye was entirely normal on examination. Fluorescein angiography showed delayed filling and late venous leakage. There was no significant capillary closure. No macular edema was seen on FFA. The choroid showed poor filling throughout the angiogram.

These findings supported a diagnosis of non-ischaemic CRVO combined with Cilioretinal artery occlusion. However, the presence of venous sheathing was at the time considered by us to represent inflammatory activity. We therefore organised several tests including FBC, ESR, Urine complete, Glucose, CRP, angiotensin converting enzyme levels, serology for toxoplasmosis, syphilis, Varicella, CMV and Mantoux test. He also underwent X-ray chest. All these tests were reported as normal. He had no systemic features suggestive of Bechet's disease. Carotid Doppler scanning showed no narrowing. His blood pressure in clinic was noted to be 188/95 and his general practitioner was informed about this.



**Fig. 1:** Colour fundus photo of Right eye at presentation. Note the vascular sheathing. OCT scan shows inner retinal hyper-reflectivity.



**Fig. 2:** Colour fundus photo of Right eye at 4 weeks. Spontaneous resolution of vascular sheathing and tortuosity is seen. OCT scan appears almost normal.

The patient was commenced on aspirin 75 mg daily and no other treatment was given. He was reviewed in clinic 2 weeks later. By then the VA had

spontaneously improved to 6/24 and there was considerable reduction in the retinal haemorrhages and vascular tortuosity. Furthermore, the previously observed vascular sheathing had completely resolved. Two weeks later VA had improved to 6/18 and OCT scan showed no retinal swelling (Fig. 2). We continued to monitor him in clinic. FFA was repeated which showed normal retinal and choroidal filling. 6 months later VA had improved to 6/12.

## DISCUSSION

The interesting aspects of this case are the transient nature of the non-inflammatory vascular sheathing, and the spontaneous visual improvement without any active treatment.

Transient non-inflammatory venous sheathing has been reported before. One report describes this phenomena following trauma<sup>6</sup>. In the context of retinal vein occlusions, there is a report of four cases. Lightman, Foss et al<sup>7</sup> described cases of retinal vein occlusion that demonstrated transient vessel wall sheathing which then resolved spontaneously. However, this is the first published report of this phenomenon seen in the setting of combined non-ischaemic CRVO and Cilioretinal artery occlusion. The reason for the sheathing is unknown.

The occlusion of the Cilioretinal artery in this situation is considered a secondary occurrence following the initial CRVO. It is thought to be due to increased hydrostatic pressure within the lamina cribrosa, which then leads to a hemodynamic stagnation within the Cilioretinal artery<sup>8</sup>. Spontaneous visual improvement following combined CRVO and Cilioretinal artery occlusion has been well described by Hayreh in his extensive paper<sup>9</sup>. It is thought to be due to the mostly extradural course adopted by the Cilioretinal artery, which protects it to some extent from the increased hemodynamic pressure in the lamina cribrosa.

## Financial Support

Nil.

## Conflict of Interest

There is no conflict of interest.

## Author's Affiliation

Dr. Imran Akram, MBBS, FRCS, FRCOphth  
Consultant ophthalmic & vitreoretinal surgeon

**Role of Authors**

Dr. Imran Akram

Sole author. Treating physician. Preparing of manuscript. Literature search. Corresponding author.

**REFERENCES**

1. **Kim IT, Lee WY, Choi YJ.** Central retinal vein occlusion combined with Cilioretinal artery occlusion. *Korean J Ophthalmol.* 1999 Dec; 13 (2): 110-4.
2. **Murray DC, Christopoulou D, Hero M.** Combined central retinal vein occlusion and Cilioretinal artery occlusion in a patient on hormone replacement therapy. *Br J Ophthalmol.* 2000 May; 84 (5): 546.
3. **Theoulakis PE, Livieratou A, Petropoulos IK et al.** Cilioretinal artery occlusion combined with central retinal vein occlusion - a report of two cases and review of the literature. *Klin Monbl Augenheilkd.* 2010; 227 (4): 302-5.
4. **Berkani Z, Kitouni Y, Belhadj A et al.** Cilioretinal artery occlusion and central retinal vein occlusion-complicating hyperhomocysteinemia: a case report. *J Fr Ophthalmol.* 2013 Sep; 36 (7): 119-27.
5. **Schmidt D.** Comorbidities in combined retinal artery and vein occlusions. *Eur J Med Res.* 2013 Aug; 18 (1): 27.
6. **Kahloun R, Abroug N, Ammari W et al.** Acute retinal periphlebitis mimicking frosted branch angiitis associated with exudative retinal detachment after blunt eye trauma. *Int Ophthalmol.* 2014 Oct; 34 (5): 1149-51.
7. **Foss AJ, Headon MP, Hamilton AM, Lightman S.** Transient vessel wall sheathing in acute retinal vein occlusions. *Eye,* 1992; 6 (Pt 3):313-6.
8. **Hayreh SS, Fraterrigo L, Jonas J.** Central retinal vein occlusion associated with cilioretinal artery occlusion. *Retina,* 2008; 28: 581-594.
9. **Hayreh SS.** Acute Retinal Arterial Occlusive Disorders. *Prog Retin Eye Res.* 2011 Sep; 30 (5): 359-394.